

Embozene™ Microspheres for Treatment of Fibronodular Hyperplasia

BY JONATHAN STEINBERGER, MD, OREGON HEALTH AND SCIENCE UNIVERSITY

A 32-year-old woman presented with an incidentally diagnosed fibronodular hyperplasia (FNH) in her liver discovered 7 years prior, at which point it measured 2 X 2.3 cm. Given her lack of symptoms and the lesion's benign imaging appearance, she was followed with serial imaging since the lesion's initial discovery. The FNH was noted to be enlarging over time, most recently measuring 5 X 4.7 cm (Figure 1). Approximately 1.5 years previously, she began noticing right back/flank pain, which had worsened as the mass grew and was not relieved with NSAIDs. This prompted an ultrasound-guided biopsy of the lesion, which confirmed the diagnosis of FNH. The patient's pain was reproduced on penetration of the liver capsule during biopsy.

The patient was seen in the interventional radiology clinic, and a thorough history and physical exam were performed. Her physical exam was notable only for some mild right upper quadrant and flank tenderness. Her liver function tests, tumor markers, and coagulation profile were all within normal limits. Percutaneous treatments, including endovascular embolization and thermal ablation, were discussed in detail with the patient, and the decision was made to proceed with embolization.

PROCEDURE DESCRIPTION

The procedure was performed under moderate monitored sedation. A 5-F (1.67-mm) shaped catheter was used for visceral selection. Selective catheterization of the right hepatic artery supplying the tumor was performed using a Renegade® HI-FLO microcatheter (Boston Scientific Corporation) over a Fathom®-16 Guidewire (Boston Scientific Corporation), and the lesion demonstrated robust tumor blush on contrast injection (Figure 2). Under fluoroscopic visualization, the bland embolic mixture was delivered (approximately 1.5 mL of

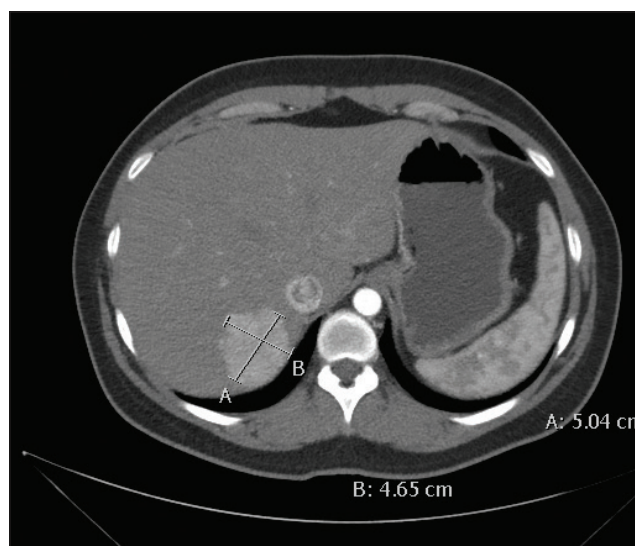


Figure 1.

lipiodol [Guerbet] emulsified with an equivalent volume of heparinized saline, followed by one half vial of 100-μm Embozene™ Microspheres [Boston Scientific Corporation]). Postembolization digital subtraction angiography was performed with the catheter unchanged in position, demonstrating stasis in the treated vessel (Figure 3). The tumor was stained with embolic material, and the procedure was completed.

FOLLOW-UP

The patient was seen in clinic 1 month postprocedure and reported a marked improvement in her symptoms (pain severity reduced to 3/10 from 8/10 preprocedure with frequent pain-free intervals). She has been able to resume regular exercise. Follow-up MRI showed stable size (5.1 X 4.4 cm) of the FNH with no arterial enhancement (Figure 4).

Results from case studies are not necessarily predictive of results in other cases. Results in other cases may vary.

A combination of emulsified lipiodol and 100- μ m Embosphere Microspheres was selected to ensure deep penetration into the vascular bed of the tumor for complete bland embolization.

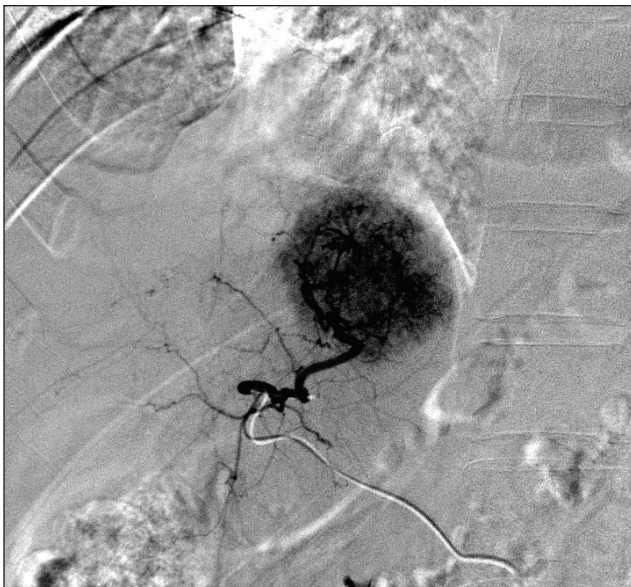


Figure 2.

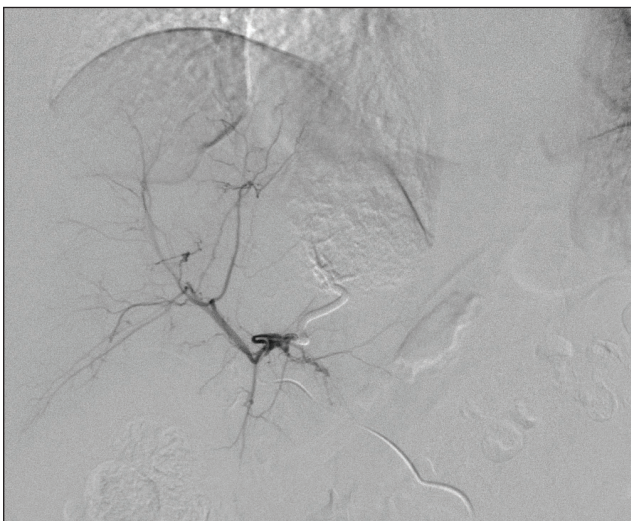


Figure 3.

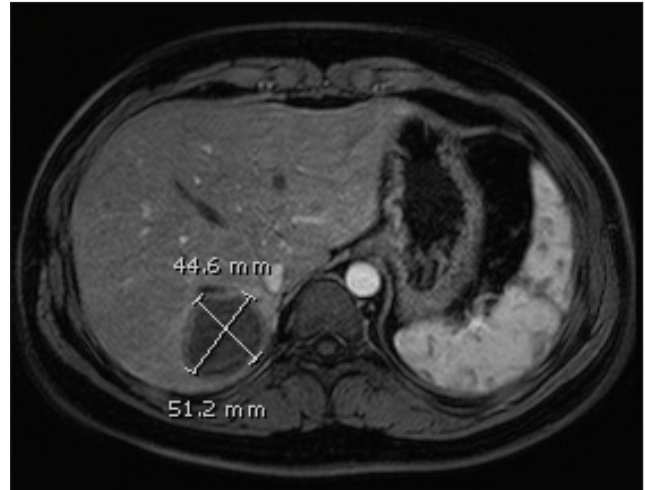


Figure 4.

DISCUSSION

Given its benign and typically asymptomatic nature, FNH is not frequently encountered in interventional radiology practices. Surgical treatment is generally considered first-line treatment for symptomatic FNH. However, in cases such as this where tumor growth or capsular distension causes symptoms and/or in those who are not surgical candidates, patients may benefit from embolotherapy or ablation.^{1,2} Given the lesser sedation requirements, growth retardation, and lesser bleeding risk of embolization, it is likely a better initial treatment option. A variety of embolic agents and particle types have been described in the literature.^{1,3} In this patient, a combination of emulsified lipiodol and 100- μ m Embosphere™ Microspheres was selected to ensure deep penetration into the vascular bed of the tumor for complete bland embolization. ■

1. Birn J, Williams TR, Croteau D, et al. Transarterial embolization of symptomatic focal nodular hyperplasia. *J Vasc Interv Radiol.* 2013;24:1647-1655.
2. Hedayati P, VanSonnenberg E, Shamos R, et al. Treatment of symptomatic focal nodular hyperplasia with percutaneous radiofrequency ablation. *J Vasc Interv Radiol.* 2010;21:582-585.
3. Amesur N, Hammond JS, Zajko AB, et al. Management of unresectable symptomatic focal nodular hyperplasia with arterial embolization. *J Vasc Interv Radiol.* 2009;20:543-547.



Jonathan Steinberger, MD

Assistant Professor
Dotter Interventional Institute
Oregon Health and Science University
Portland, Oregon, USA

Disclosures: Consultant for Ethicon; founder of Madorra.